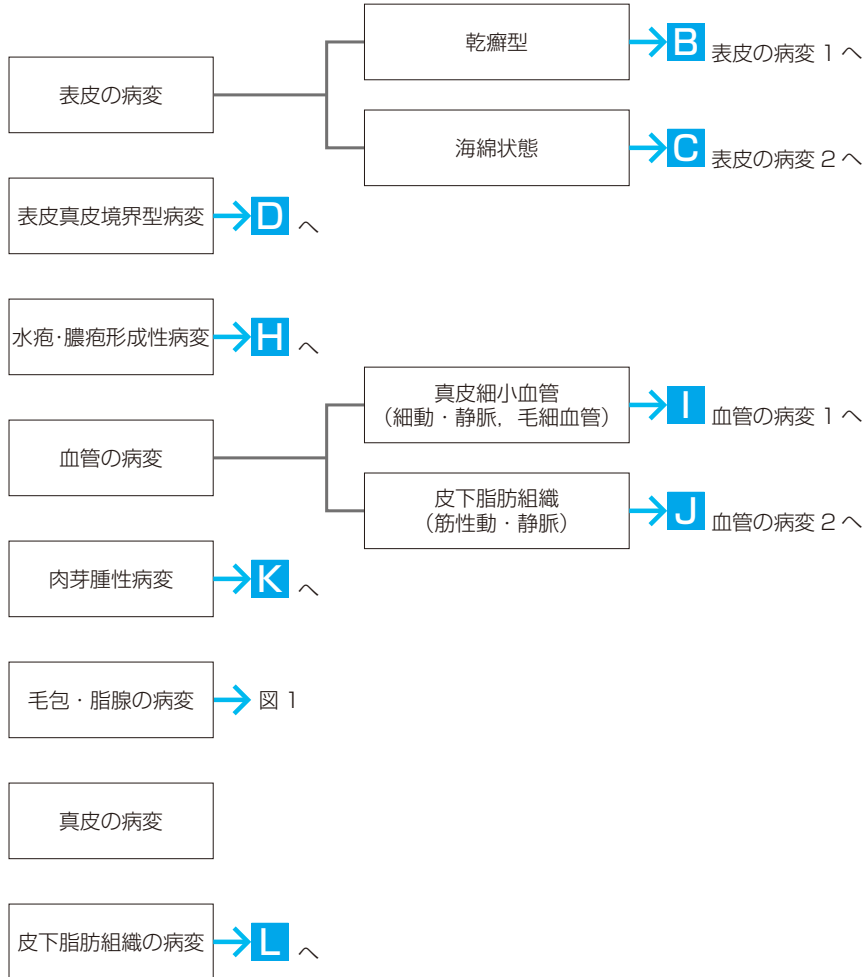


〈付録〉 炎症性疾患を診断するためのアルゴリズム

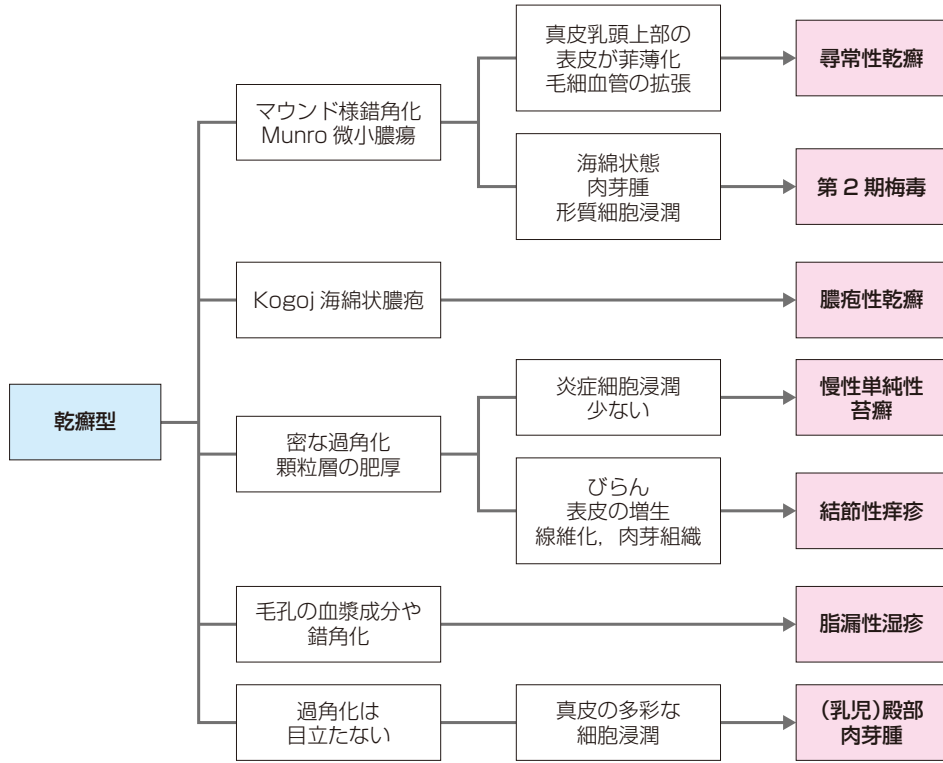
(泉 美貴)

A 炎症性病変の病理組織パターン

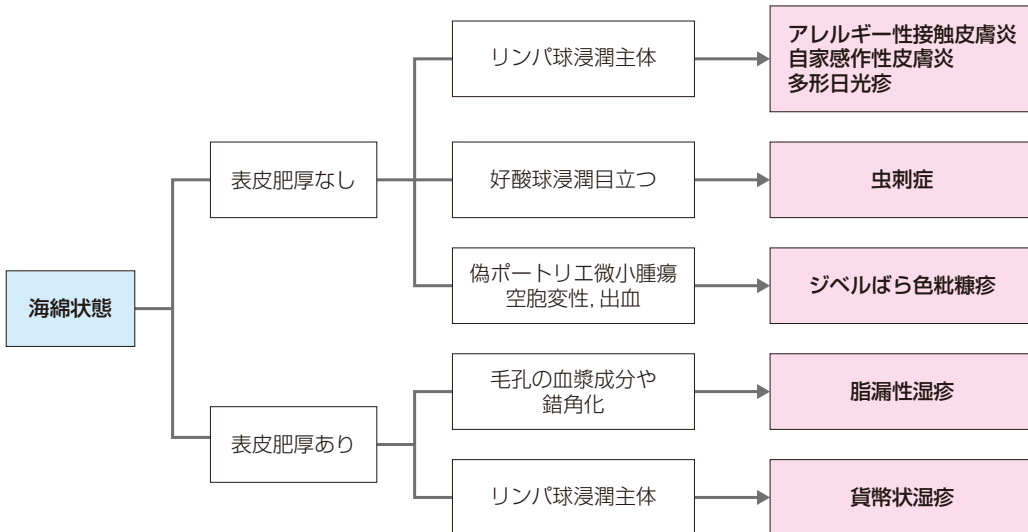


(泉 美貴, 檜垣祐子. みぎ先生とゆう子先生の皮膚病理診断 ABC ④炎症性病変. 学研メディカル秀潤社; 2013 より一部改変)

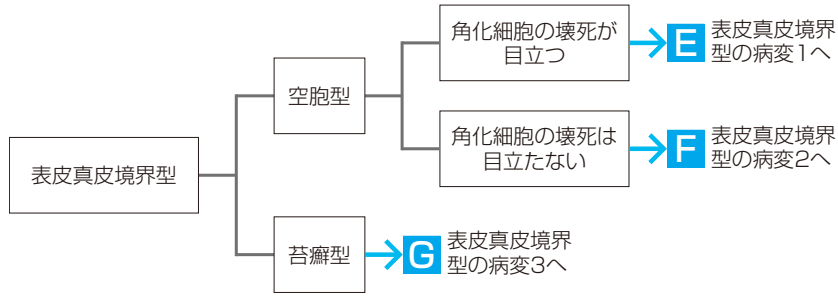
B 表皮の病変 1—乾癬型



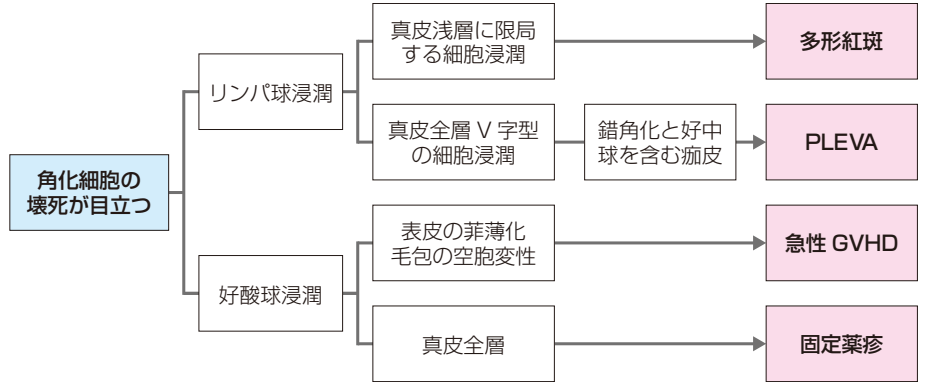
C 表皮の病変 2—海綿状態



D 表皮真皮境界型の病変

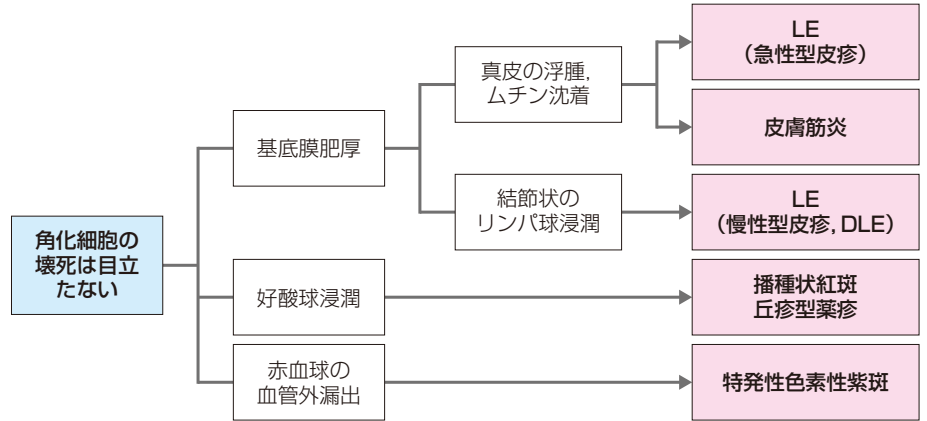


E 表皮真皮境界型の病変 1—空胞型①(角化細胞の壊死が目立つ)



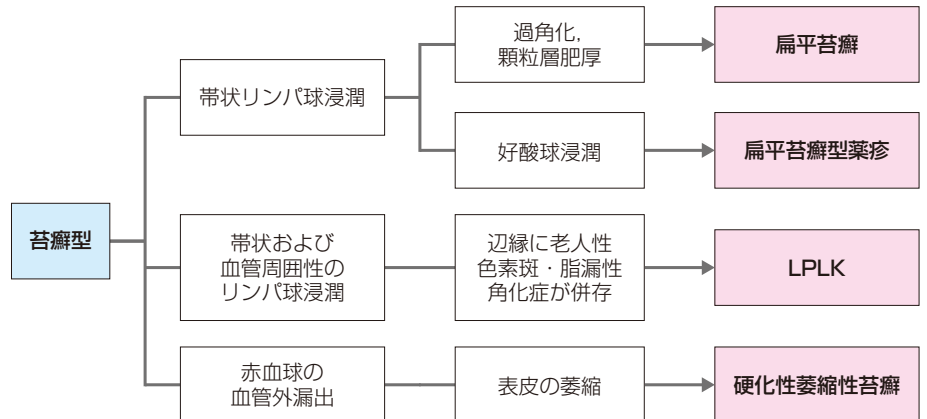
PLEVA : pityriasis lichenoides et varioliformis acuta, GVHD : graft versus host disease

F 表皮真皮境界型の病変 2—空胞型②(角化細胞の壊死が目立たない)



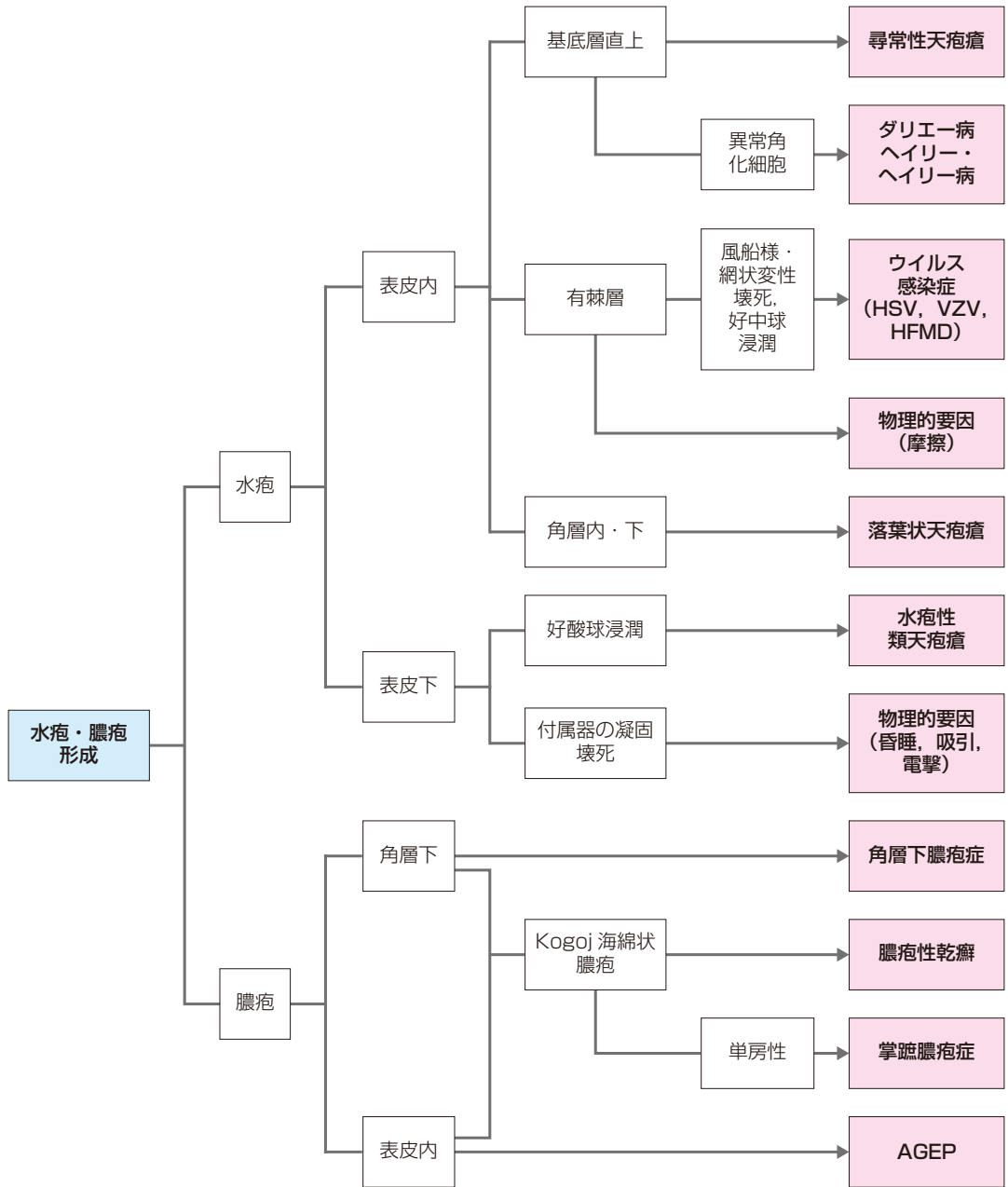
LE : lupus erythematosus, DLE : discoid lupus erythematosus

G 表皮真皮境界型の病変 3—苔癬型



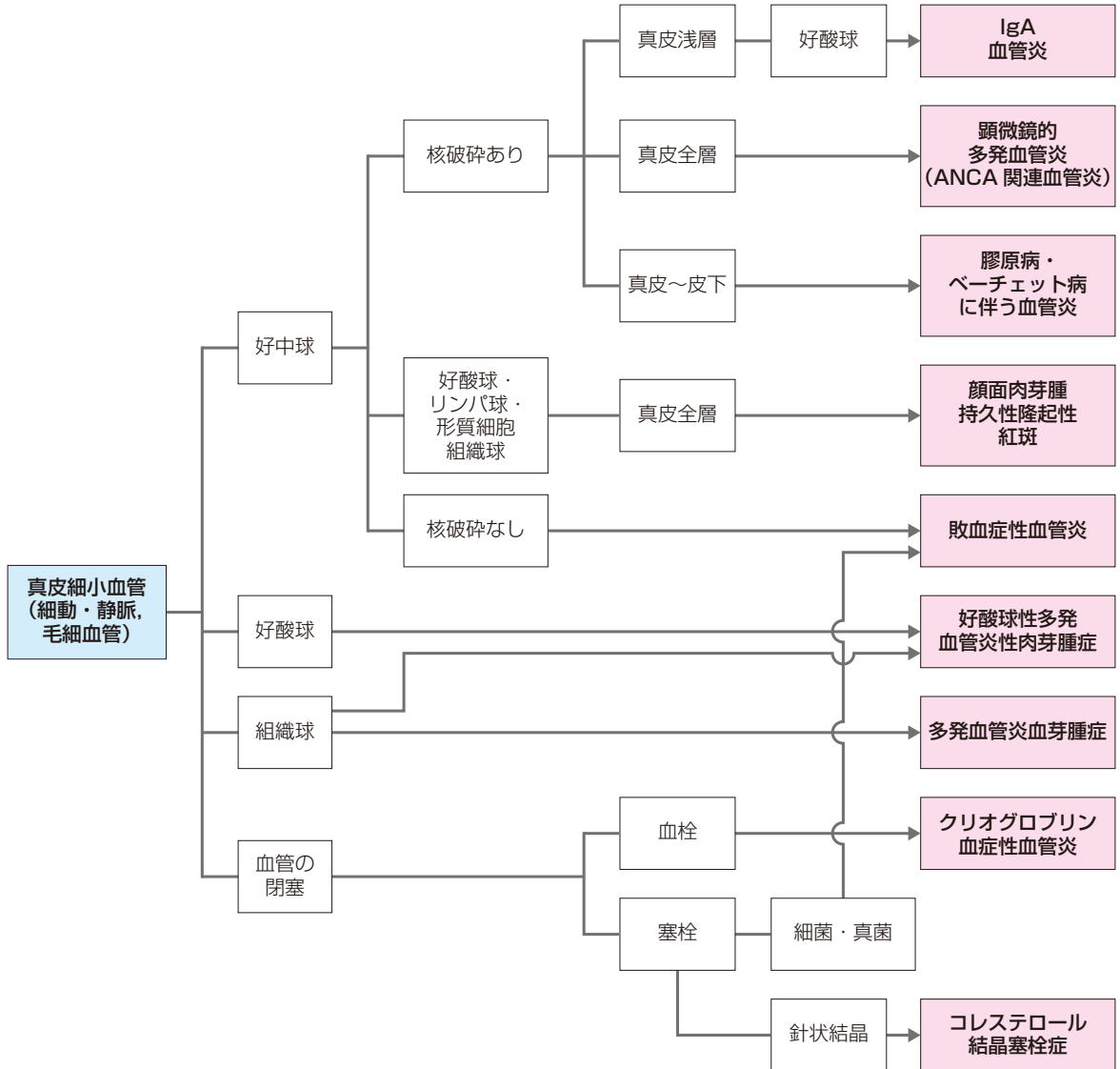
LPLK : lichen planus-like keratosis

H 水疱・膿疱形成性病変

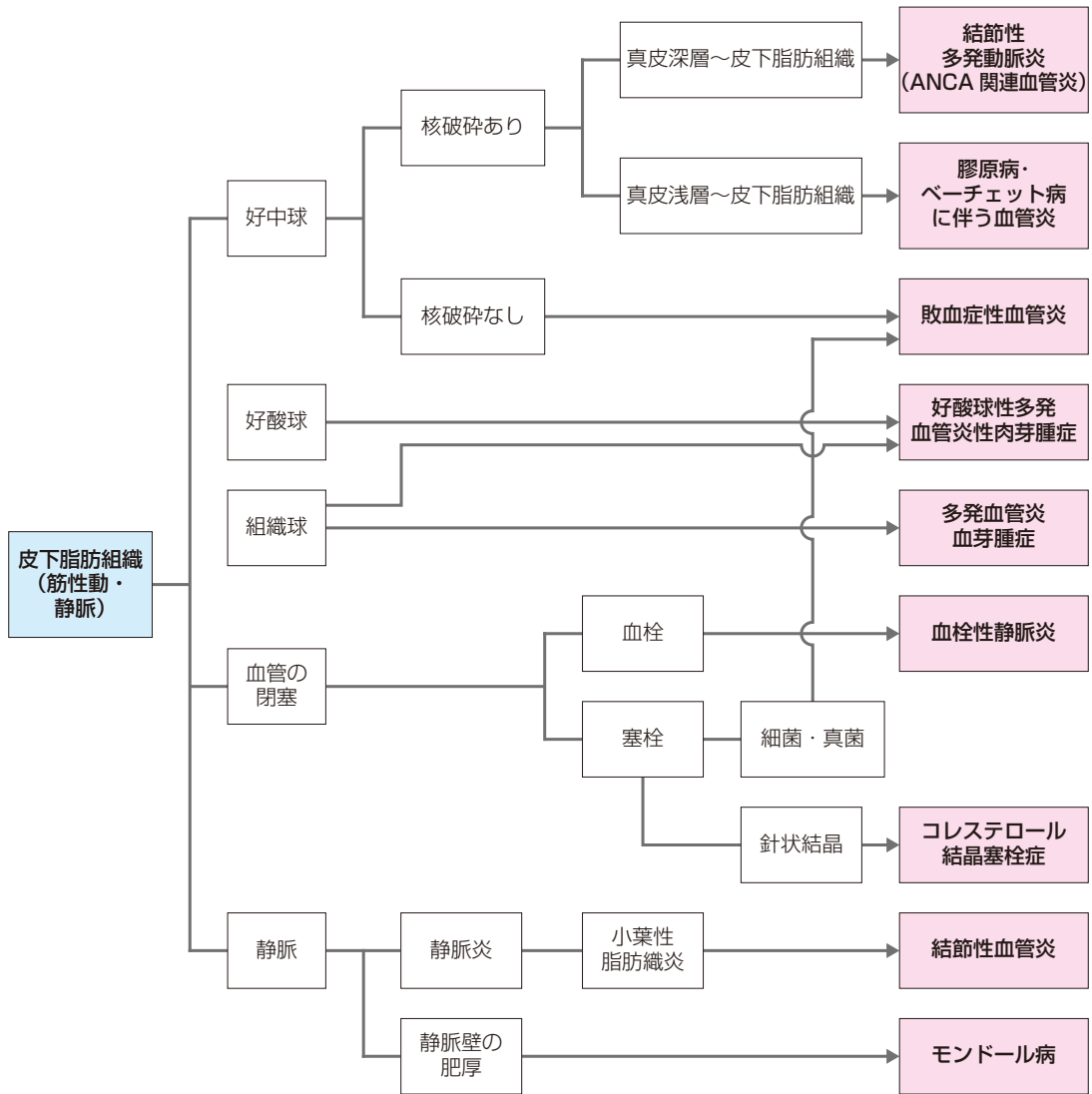


HSV : herpes simplex virus, VZV : varicella zoster virus, HFMD : hand, foot and mouth disease.
 AGEP : acute generalized exanthematous pustulosis

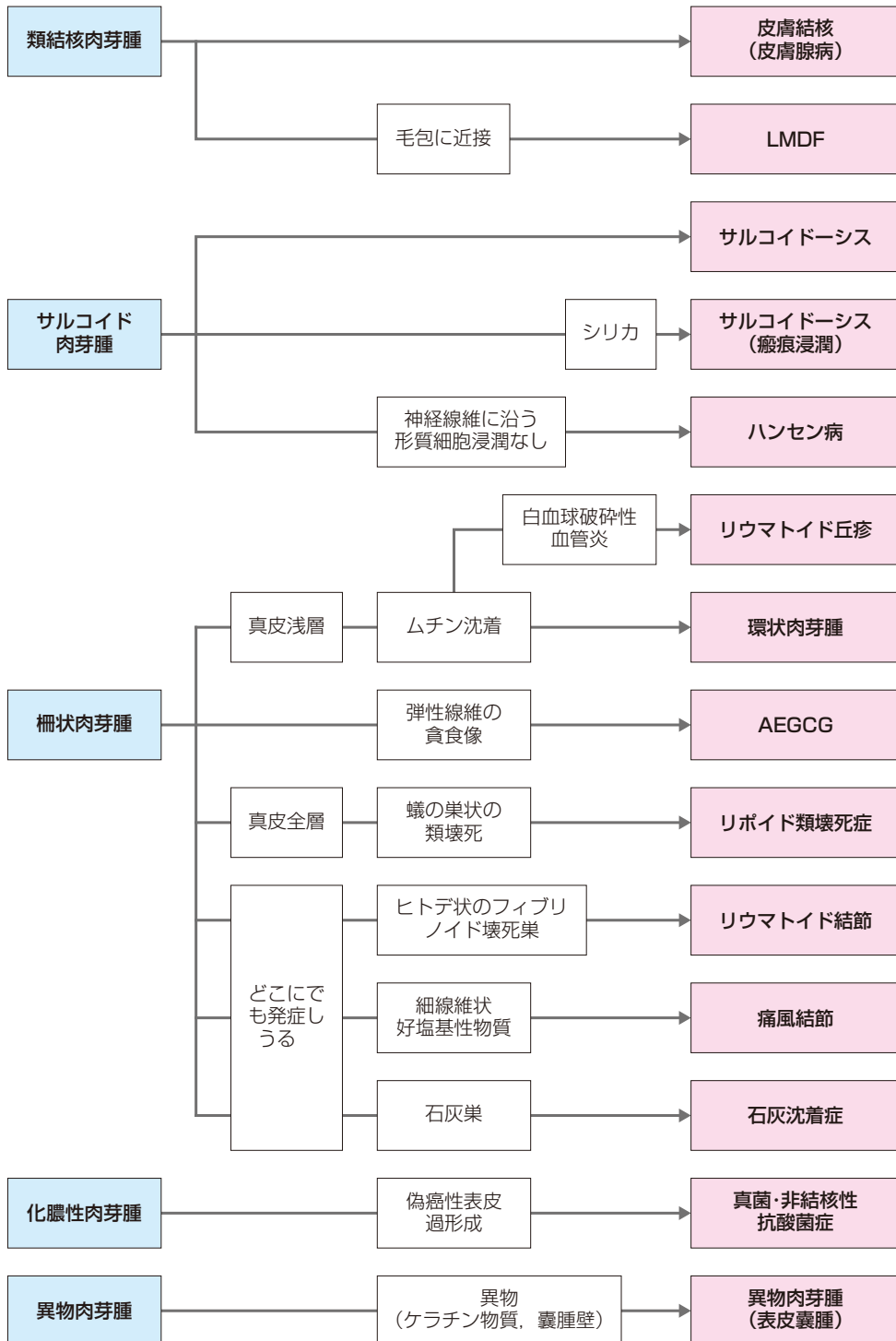
I 血管の病変 1—真皮細小血管（細動・静脈，毛細血管）



J 血管の病変 2—皮下脂肪組織（筋性動・静脈）



K 肉芽腫性病変



L MDF : lupus miliaris disseminatus faciei (顔面播種状粟粒性狼瘡), AEGCG : annular elastolytic giant cell granuloma (環状弾性線維融解性巨細胞肉芽腫)

L 皮下脂肪組織の病変

